

COMPLICATIONS OF THE THIRD STAGE OF LABOUR

- 1-Postpartum haemorrhage
- 2-Retention of the placenta
- 3-Inversion of the uterus
- 4-Obstetric shock

Postpartum haemorrhage

- Definition

- Incidence

- Types

Primary postpartum haemorrhage

■ Aetiology

A-Placental site bleeding

1-Atonic

2-Retained products

3-Coagulopathies

B-Traumatic

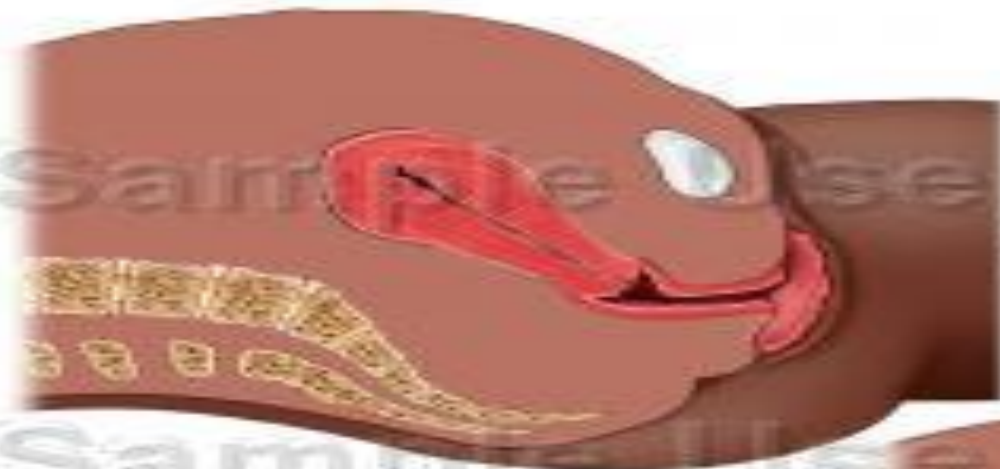■ Clinical pictures:

A-General Examination

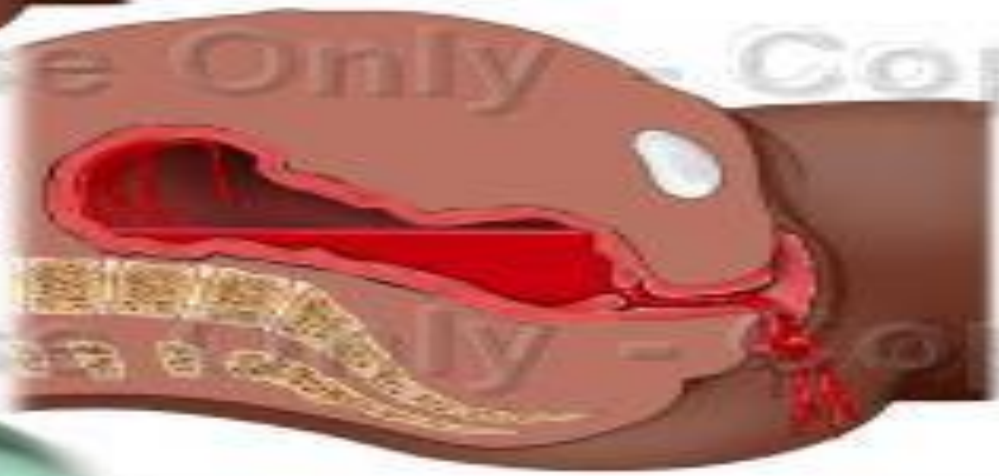
B-Abdominal examination

C-Vaginal Examination

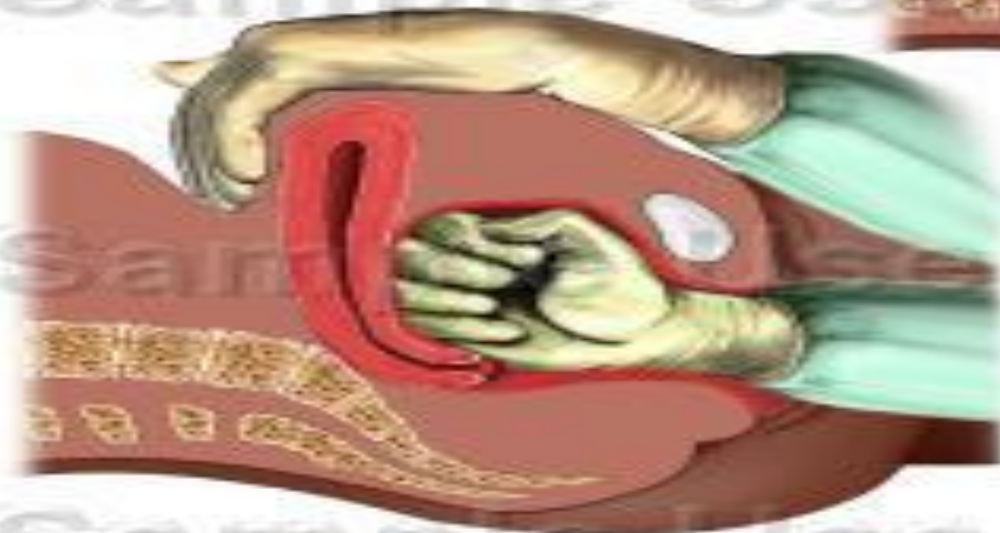Uterine Atony and Postpartum Hemorrhage with Fundal Massage



Normal postpartum condition with contracted uterus preventing hemorrhage.



Uterine atony allows hemorrhage to flow into the uterus.



Manual fundal massage squeezing of the uterus in an attempt to stop the hemorrhage.

Treatment of Primary PPHge

■ A- prophylactic:

1-Antepartum

2-Intrapartum

3-Postpartum

■ B-Active Treatment

■ Antishock measures

1-Placental site bleeding

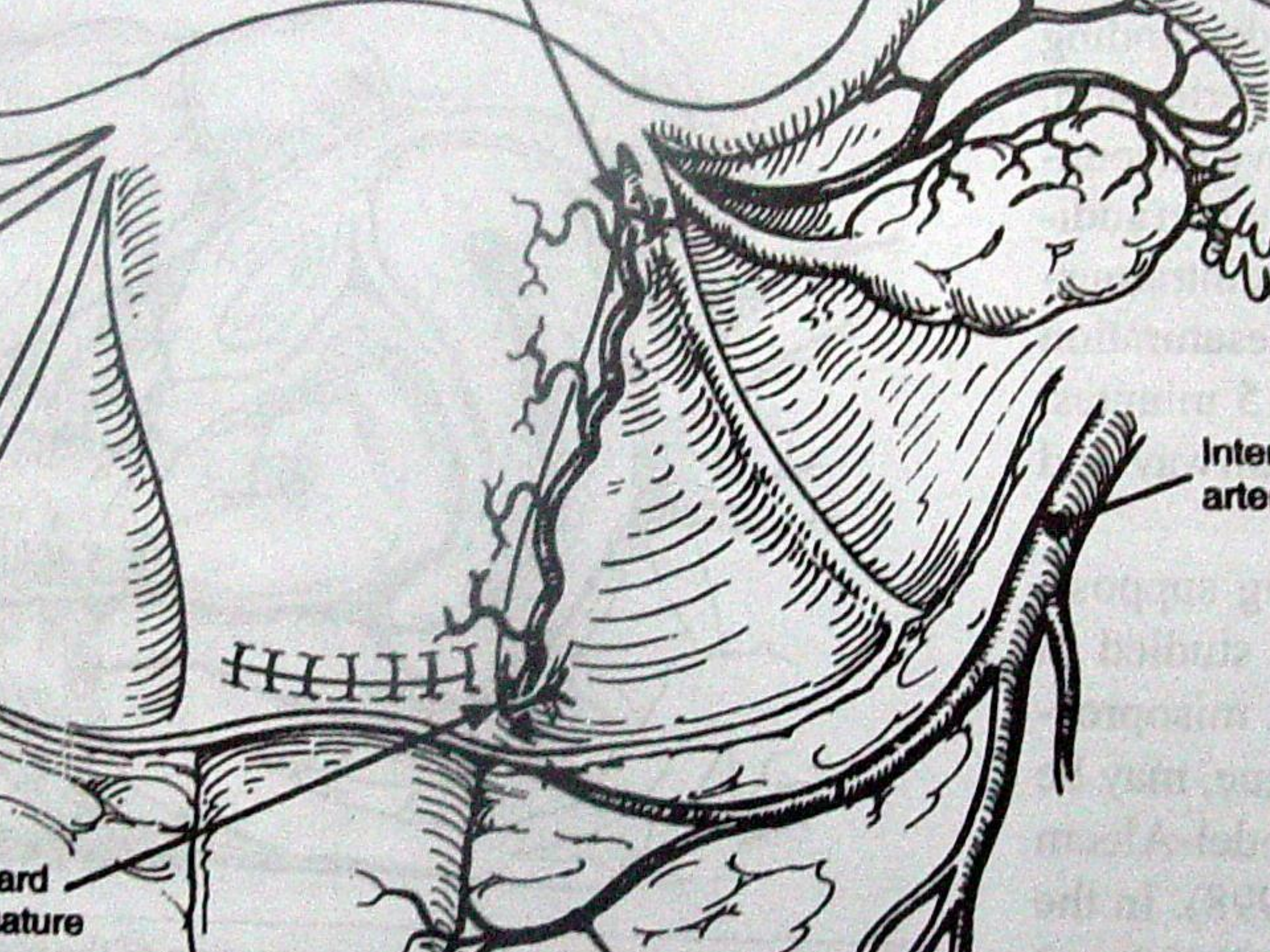
1-Retained products

2-Coagulopathies

3-Atonic

TTT of Atonic PPHge

- 1-Mechanical
- 2-Pharmacological
- 3-Manipulative
- 4-Surgical
- 5-Radiographic
- 6-Topical haemostatic agents



Inter
arte

ard
ature

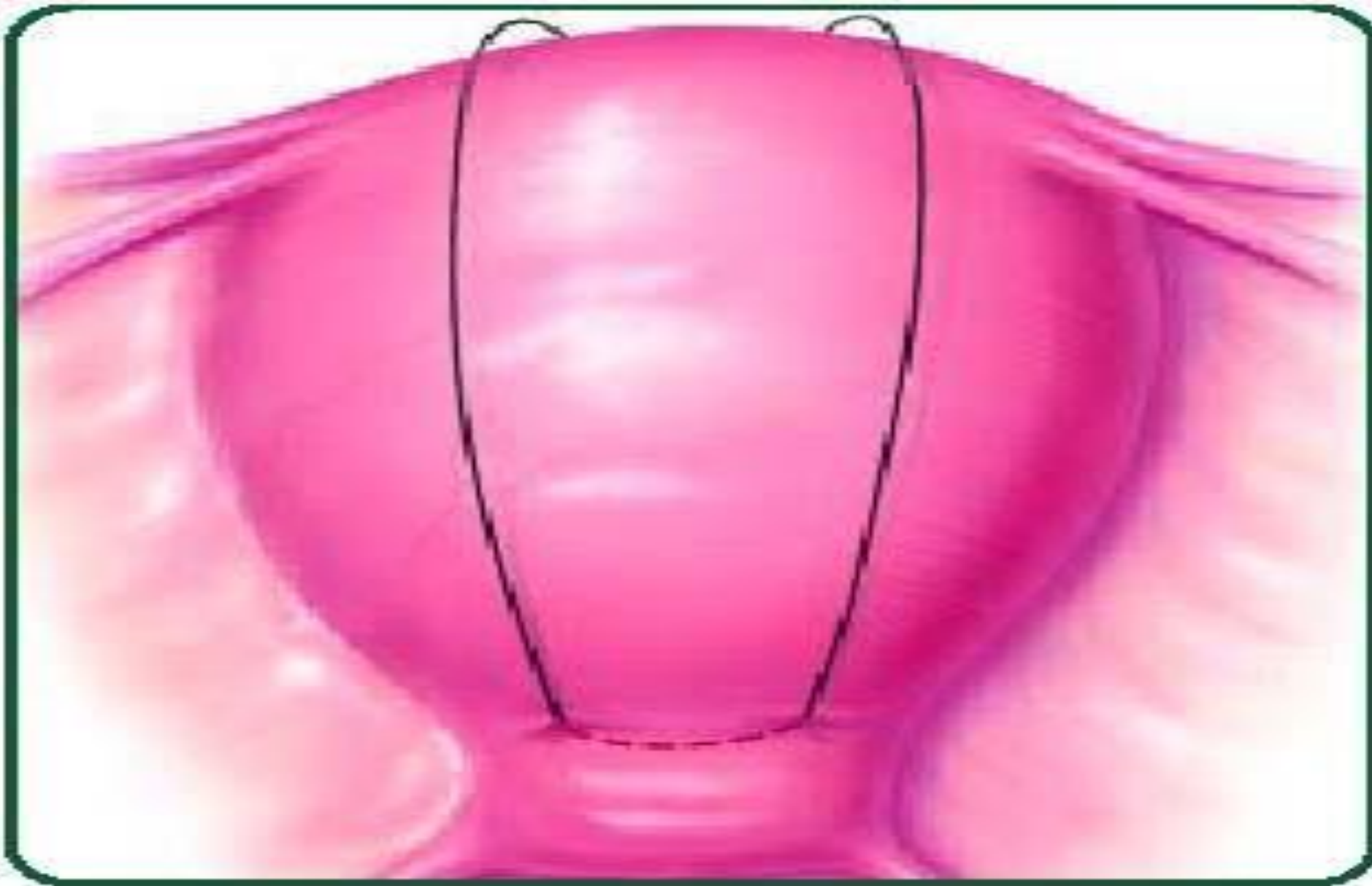


FIGURE 2. Next the suture is carried on the outside of the uterus over the anterior uterine surface to the posterior side and inserted through the posterior uterine wall at site 3. (Here the suture is in place but has not yet been tied.)

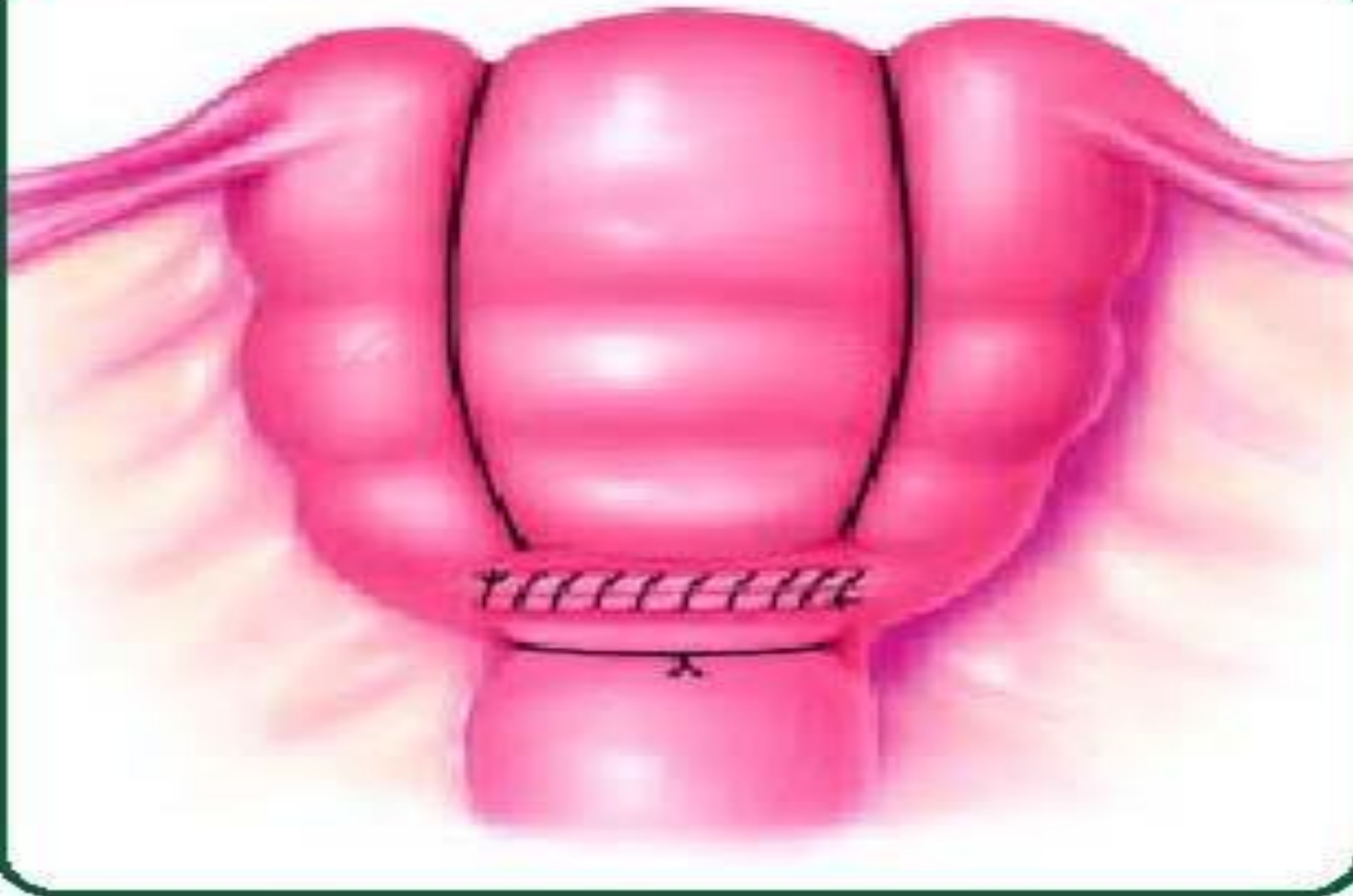
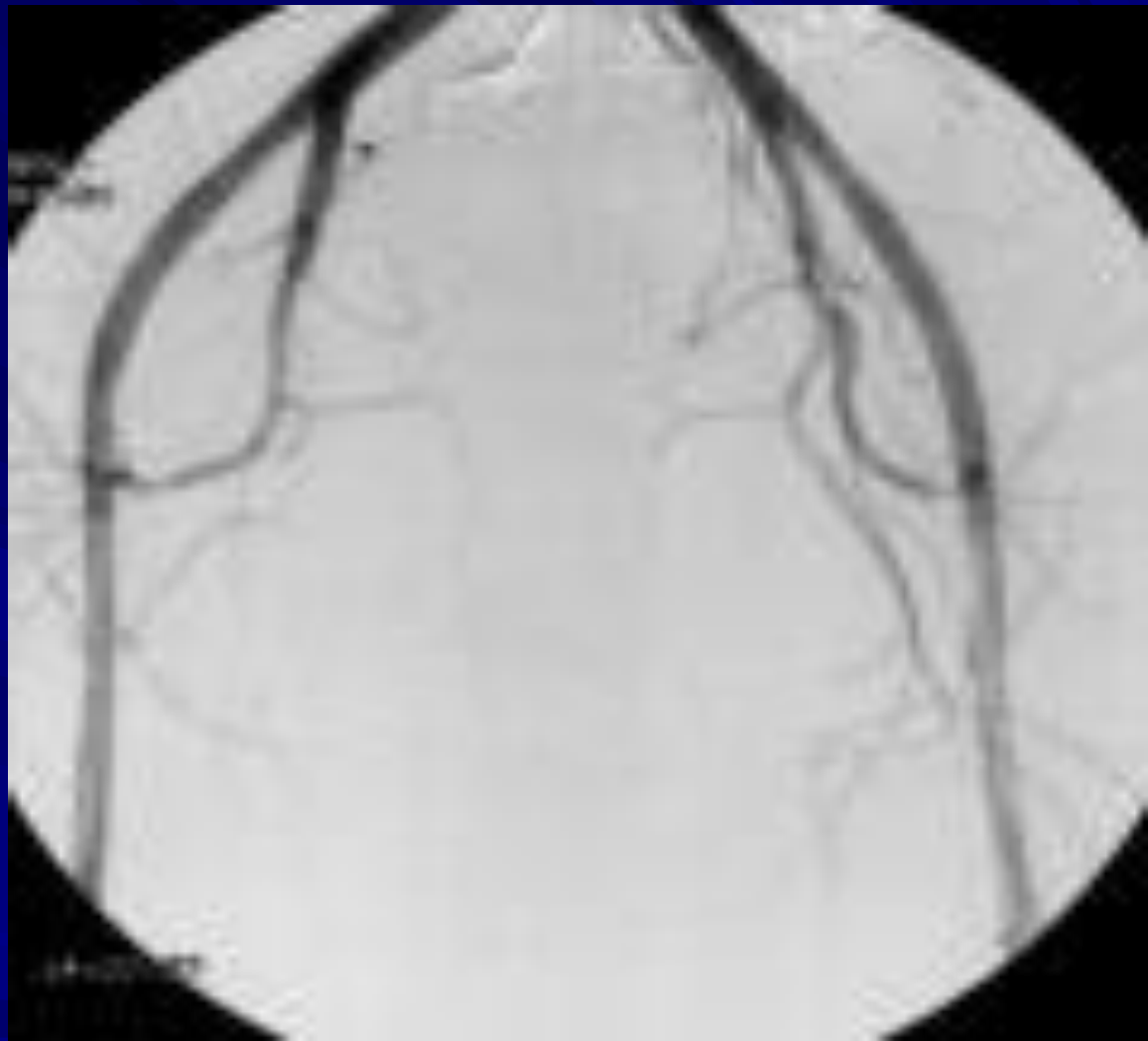
FIGURE 3. The suture is tied as the assistant tightly compresses the uterus. The B-Lynch suture is in place in this view of the compressed uterus after the hysterotomy incision has been closed.



TTT OF TRAUMATIC PPHge



Secondary PPHge

- Causes

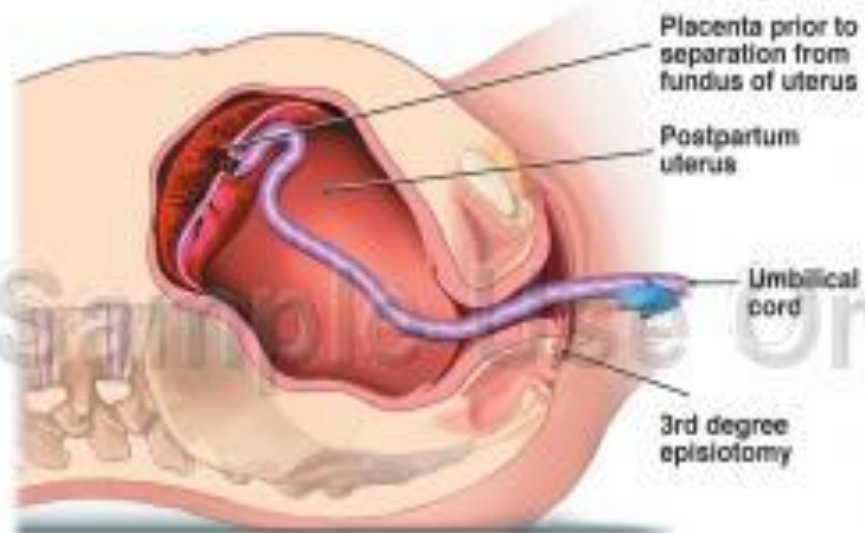
- TTT

RETAINED PLACENTA

- Definition
- Incidence
- Aetiology
- Clinical pictures
- TTT
- Complications

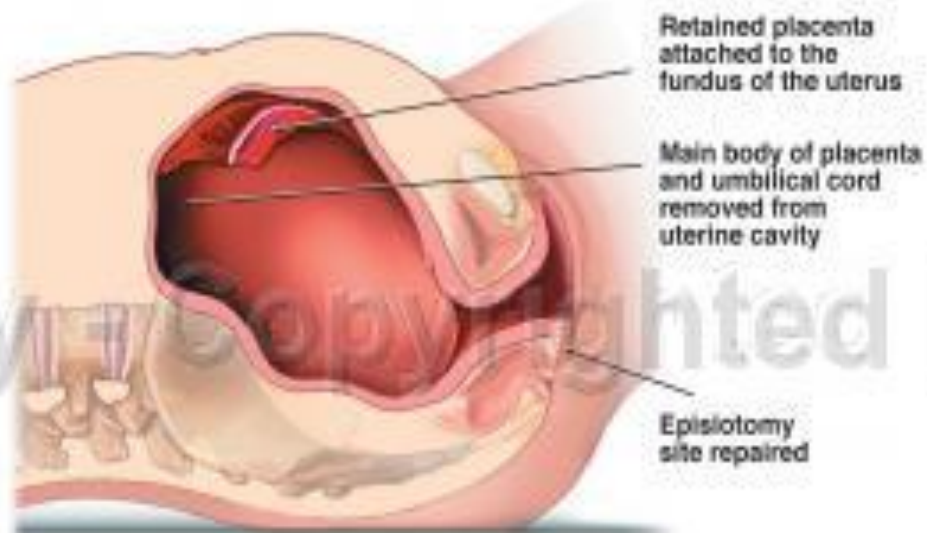
Attempts to Clear Retained Placenta Following Delivery

1. Initial Postpartum Condition

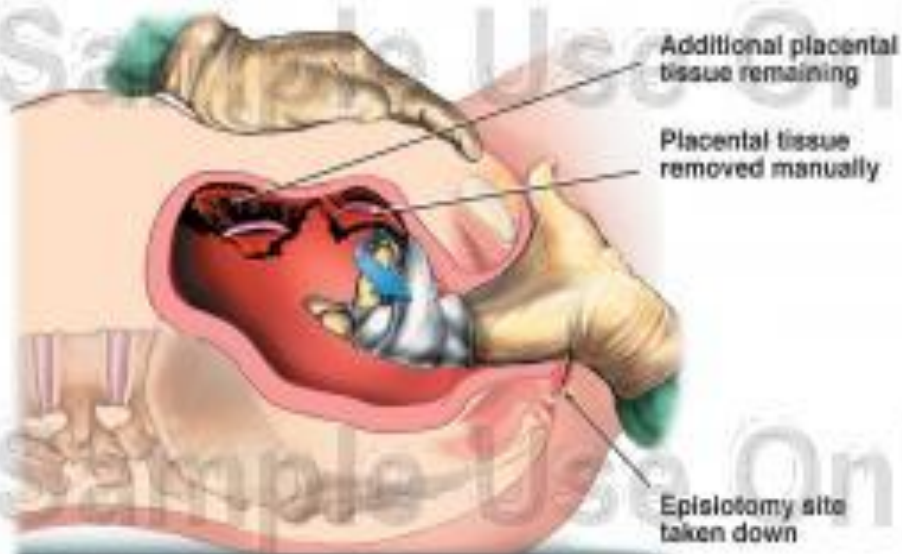


Cut-away view

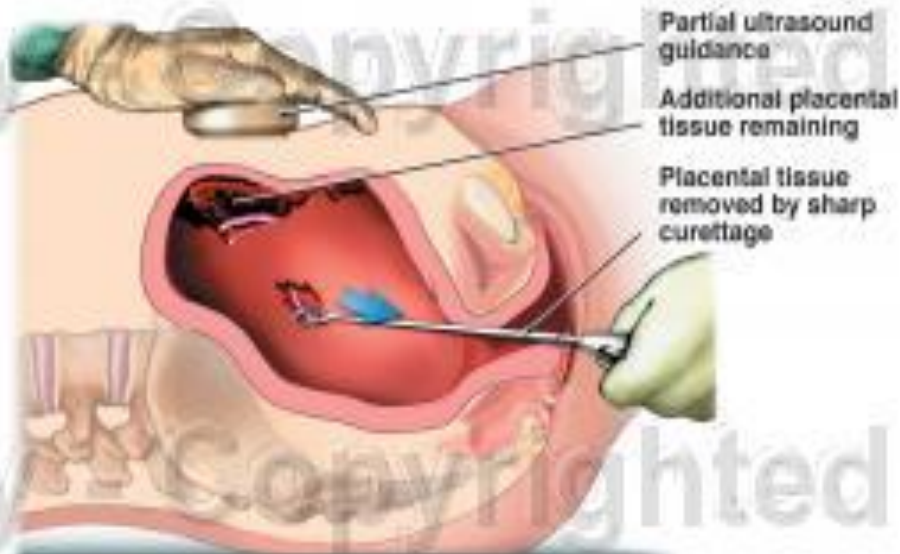
2. Condition Following Placental Delivery

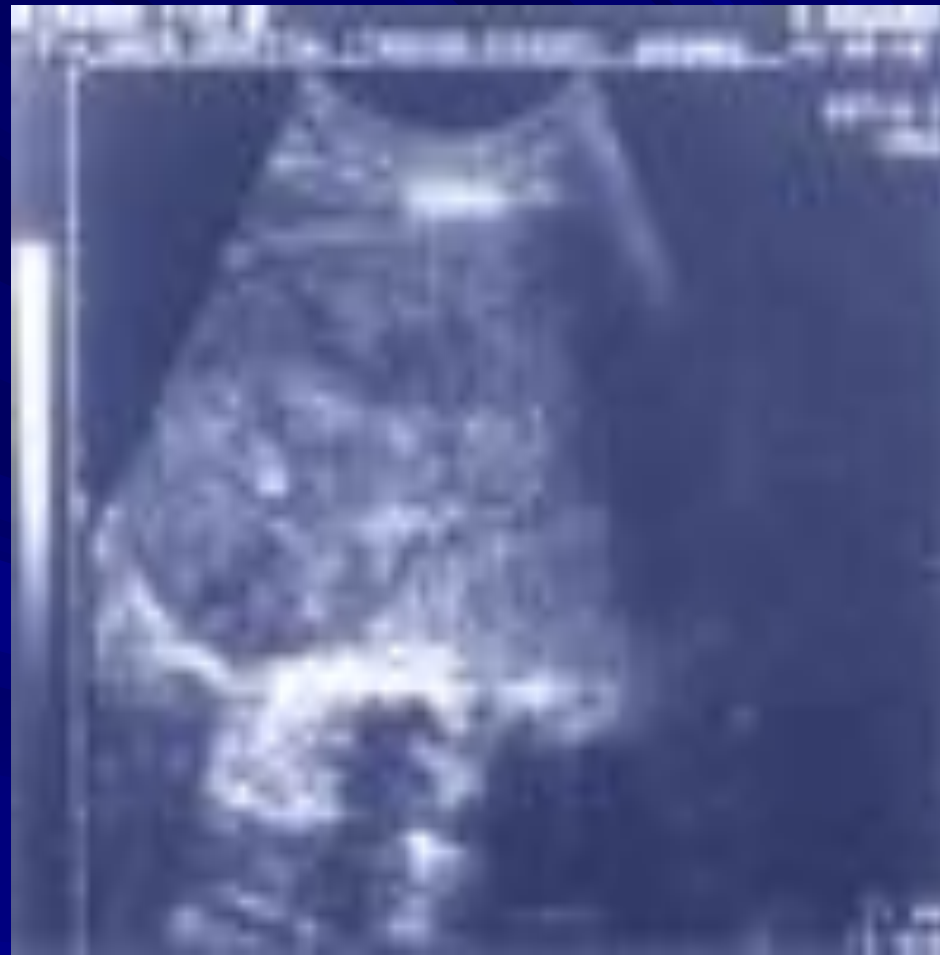

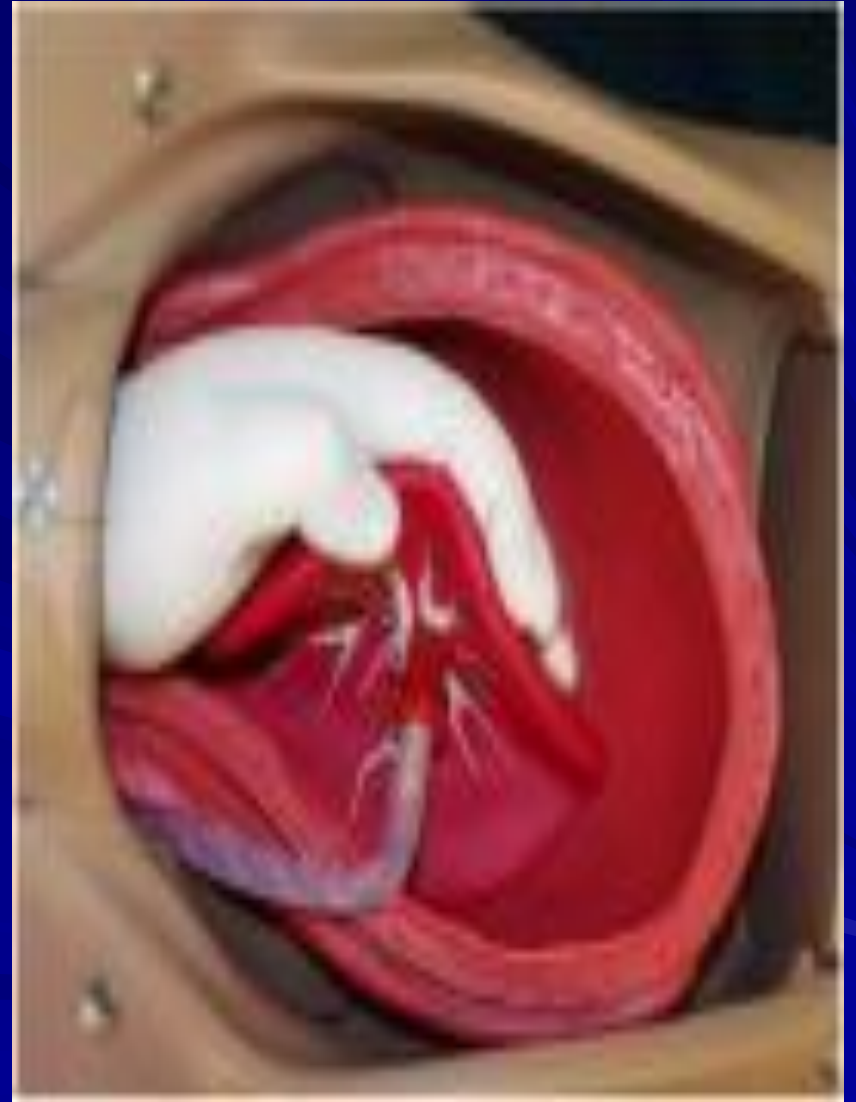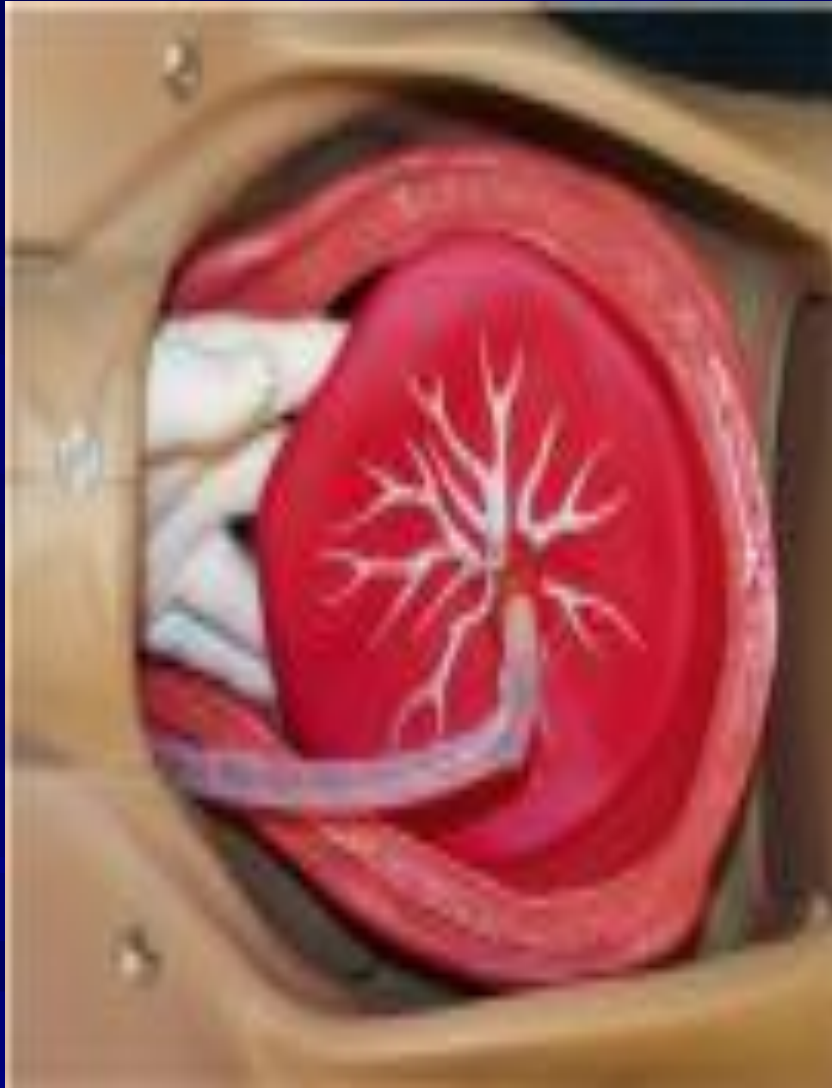3. Attempted Manual Removal



4. Attempted Removal by Sharp Curettage





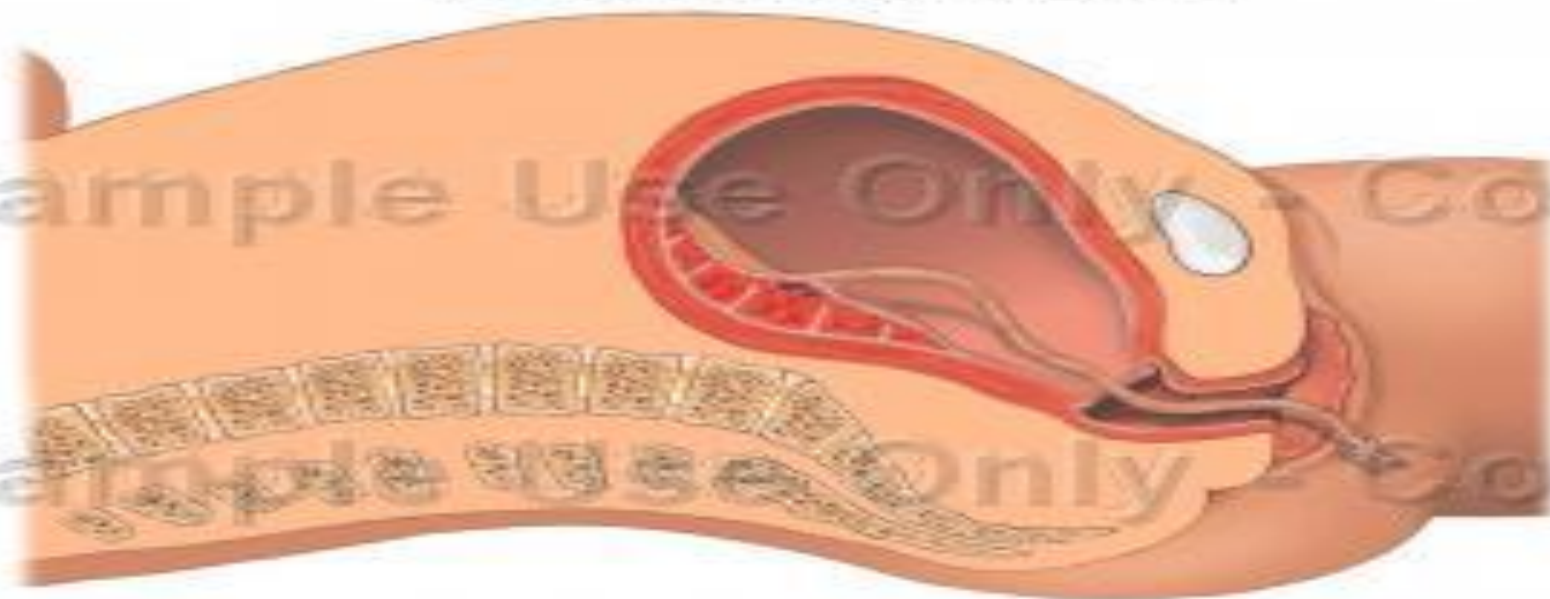


INVERSION OF THE UTERUS

- Definition
- Incidence
- Aetiology
- Degrees
- Clinical pictures
- TTT
- Chronic inversion

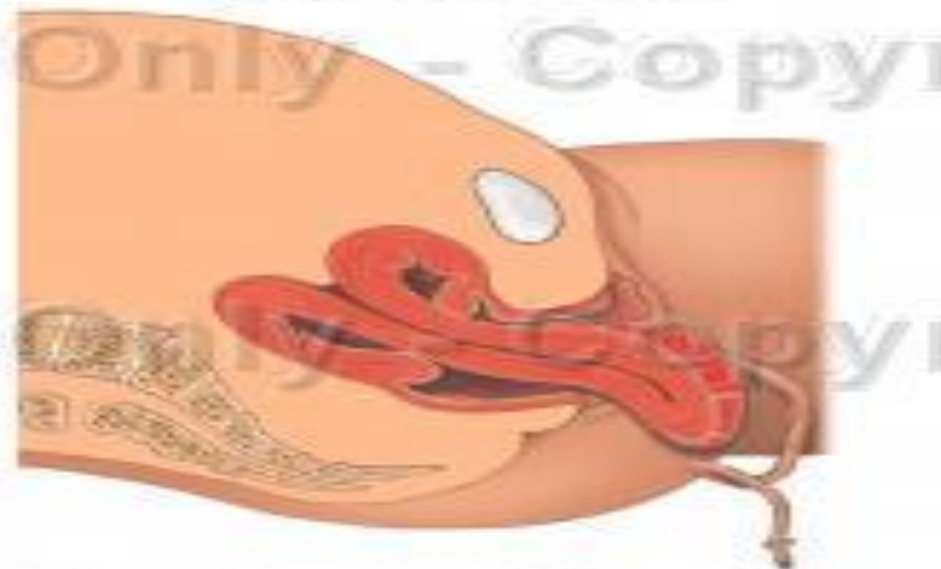
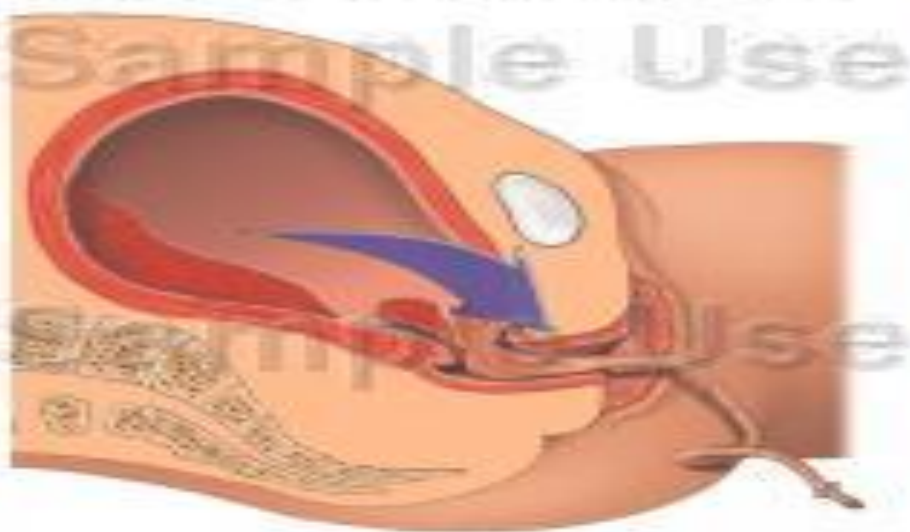
Acute Uterine Inversion - Copy

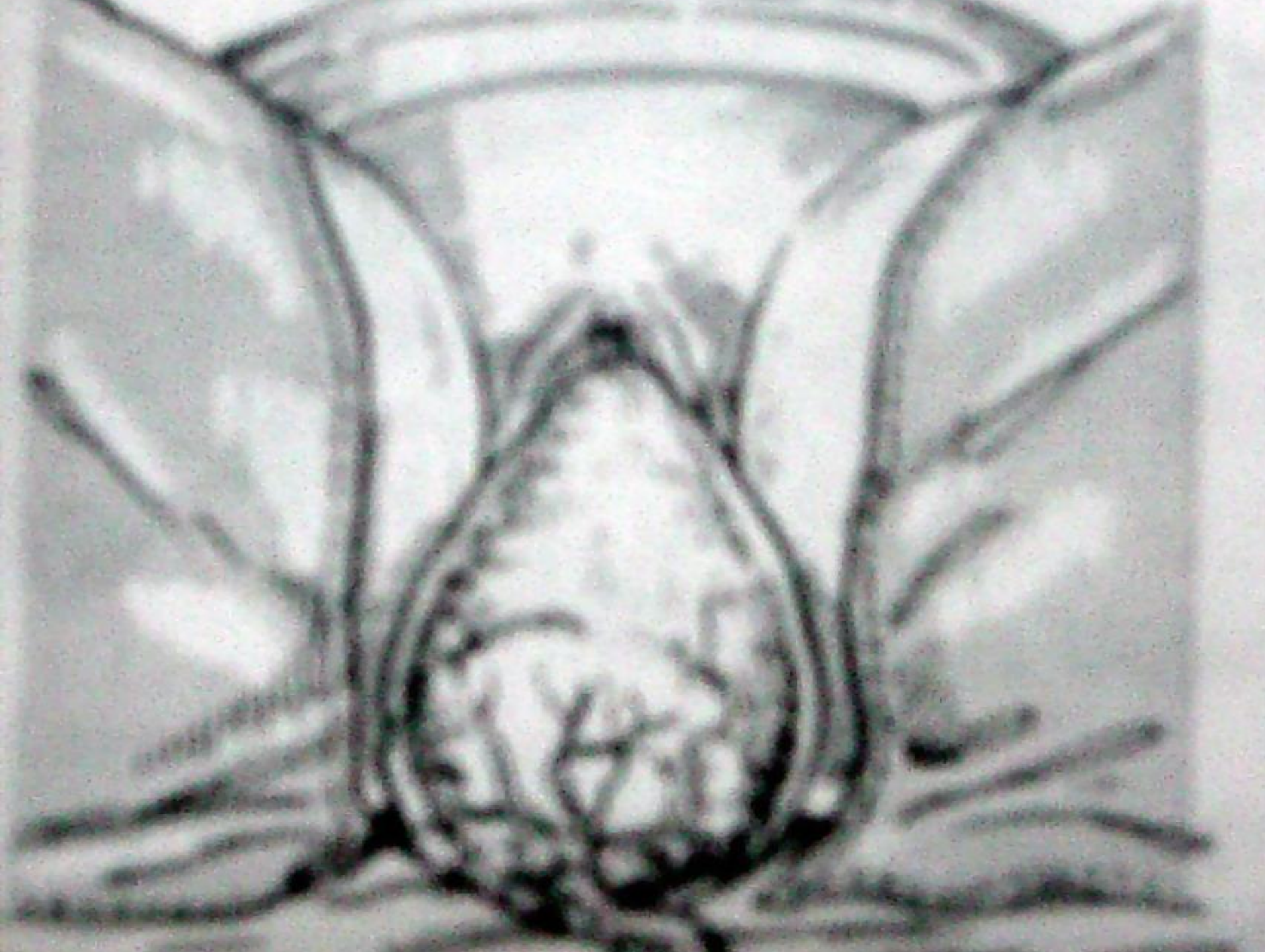NORMAL POST-PARTUM ANATOMY

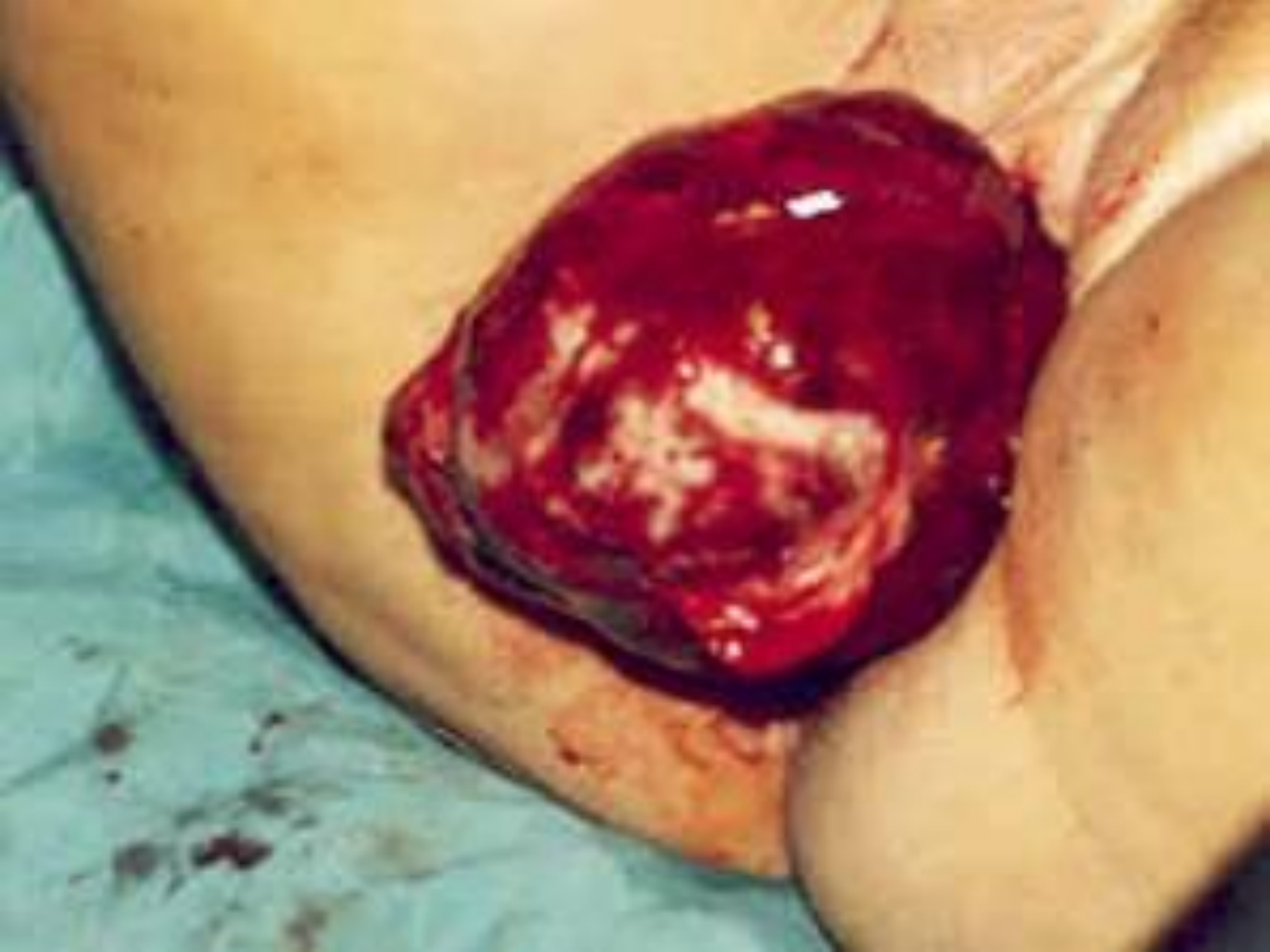

NORMAL PLACENTAL EXPULSION

UTERINE INVERSION







OBSTETRIC SHOCK

- Definition
- Types
- Clinical pictures
- TTT

HYPOFIBRINOGENAEMIA

- Definition

- Aetiology

- Diagnosis

- TTT